

## SARCOIDOSIS AND PULMONARY HYPERTENSION – A CASE REPORT

Shalini Tayal<sup>1</sup>, Norbert F. Voelkel<sup>2</sup>, Pradeep R. Rai<sup>2</sup>, Carlyne D. Cool<sup>1</sup>

<sup>1</sup>Department of Pathology, University of Colorado Health Sciences Center, Denver, Colorado, USA,

<sup>2</sup>Pulmonary Hypertension Center, University of Colorado Health Sciences Center, Denver, Colorado, USA

### Abstract

We report a case of severe pulmonary hypertension associated with sarcoidosis with a unique histopathological presentation.

This 43-year old obese patient first presented eight years ago with complaint of dyspnea on exertion for four years and was diagnosed as primary pulmonary hypertension. Six years later, a skin biopsy performed on her left cheek to rule out squamous cell carcinoma revealed sarcoidosis. The patient was then put on steroid therapy and subsequently, the oxygen saturation improved transiently, although the mean pulmonary arterial pressure did not show improvement. The patient was then started on prostacyclin infusion and was hemodynamically stable, but the pulmonary artery pressures worsened. The patient died from complications subsequent to a diagnostic procedure.

An autopsy limited to the lungs was performed and routinely prepared hematoxylin and eosin stained sections were examined. Immunohistochemical stains for CD31, factor VIII-related antigen and muscle-specific actin were performed on selected sections.

The diagnosis of sarcoidosis was confirmed. However, pulmonary fibrosis was not seen. The granulomas surrounded medium- and small-sized pulmonary arteries, but did not destroy the vessel wall. Plexiform lesions indicating severe pulmonary hypertension were identified in pulmonary arteries, which were not involved by granulomas.

*Key words:* Sarcoidosis, Pulmonary Hypertension, Granulomas

### INTRODUCTION

Pulmonary hypertension is a known but uncommon presentation of sarcoidosis. Pulmonary hypertension has been reported in 1-4% of all sarcoidosis patients [1], whereas sarcoidosis is a granulomatous systemic disease of unknown etiology with exacerbations and remissions. We report a case of severe pulmonary hypertension, the clinical picture of which was very confusing. The initial diagnosis was Idiopathic Pulmonary Arterial Hypertension (IPAH). However, after a diagnosis of sarcoidosis was made, the patient did not respond well to systemic corticosteroid therapy, but remained hemodynamically stable with prostacyclin infusion. She unfortunately died of procedural complica-

tions before a double lung transplant or heart-lung transplant could be scheduled. The histology of the lung did not show parenchymal fibrosis but did contain plexiform lesions, as well as well-formed granulomas. We believe that this observation is important in light of the recent publication of a series of cases of patients with pulmonary hypertension and sarcoidosis where no plexiform lesions had been reported [2].

### CASE REPORT

The patient, a 43-year old obese female with a 15 pack-year history of smoking, was diagnosed with primary pulmonary hypertension in 1993. Her mean pulmonary arterial pressure was 65mmHg at that time. Her cardiac output was 5.7 with a cardiac index of 2.8. Her pulmonary hypertension was tested for reversibility with nitroprusside infusion resulting in a drop of the mean pulmonary arterial pressure to 46mmHg. With 100% oxygen, her mean pulmonary arterial pressure was 49mmHg. The oxygen saturation was 95% at rest and 91% with exercise. The chest x-ray was remarkable for large pulmonary arteries and right ventricular enlargement. She had a widely split and prominent S2 which increased with inspiration. Her weight at that time was 235 pounds. The severe pulmonary hypertension was initially thought by her primary care physician to be related to her obesity. Because of her obesity, lung transplantation was not considered at that time. Another right heart study performed in October 1996 showed the mean pulmonary arterial pressure to be 71mmHg. The cardiac output was 3.1 with a cardiac index of 1.5. Because of her worsening cardiac output and index and her lack of response to low or high-flow oxygen, she was now thought to have primary pulmonary hypertension and considered a candidate for lung transplant. A sleep study done in January 1997 did not show evidence of sleep apnea. A heart catheter study done in February of 1997 showed a mean pulmonary arterial pressure of 76 mmHg, right atrial pressure of 15 mmHg, pulmonary wedge pressure of 11mmHg and a mean systemic pressure of 100 mmHg. The pulmonary vascular resistance was 1128 dynes/sec/cm. During the catheterization, prostacyclin infusion was given at 6 ng/kg. With treatment, the right atrial pressure was 16 mmHg, mean pulmonary arterial pressure was 76 mmHg and the cardiac output improved to 5.6, a 22% increase. Based on

this study, the patient was started on long-term prostacyclin infusion. An echocardiogram performed in 1998 described a mean pulmonary arterial pressure of 100 mmHg and also showed tricuspid regurgitation. A chest x-ray at this time reported areas of ground glass density in the lower two-thirds of both lungs, a recognized finding in pulmonary hypertension of long standing. The patient's anti-nuclear antibody (ANA) was negative, as was her anti-centromere antibody.

A left cheek skin biopsy performed in 1999 for suspicion of squamous cell carcinoma revealed sarcoidosis. The clinical diagnosis at this point was changed to pulmonary hypertension associated with sarcoidosis. She was started on prednisone 40 mg per day, which improved her oxygenation and decreased her supplemental oxygen requirement. An echocardiogram in December 2000 showed a severely dilated right ventricle, severe tricuspid regurgitation and a high right ventricular systolic pressure (117 mmHg). The pulmonary arteries were moderately dilated and mild to moderate pulmonary valve regurgitation was present. Atrial septal defect or valvular stenosis was not seen. The lung functions showed an FVC of 3.5 (84% of predicted), an FEV1 of 2.17 (74% of predicted), a TLC at 81% of predicted, and a diffusing capacity (corrected for alveolar volume) of 78% of predicted. The patient was also found to be hypothyroid in July 2001 and was started on synthroid. In spite of continuous treatment with prostacyclin, the patient showed overall deterioration and developed symptoms of right heart failure. In July 2001, a last attempt at treating sarcoidosis with pulsed steroid therapy was made with no improvement. The lung functions performed in August 2001 showed deterioration (an FEV 3.48 - 77% of predicted, an FEV1 2.9 - 73% of predicted, and diffusion capacity - 73% of predicted).

In August 2001, transplantation was considered and, to guide the surgeons and to choose between lung/ heart-lung transplantation, a right ventricular endomyocardial biopsy was performed to rule out cardiac involvement by sarcoidosis. During the procedure, a right ventricular perforation and subsequent

cardiac tamponade occurred; this was followed by surgical repair. The pericardial and endomyocardial biopsy did not show sarcoid granulomas. The postoperative period was complicated by pneumonia, refractory hypoxia, hypotension, and atrial flutter/ tachycardia, which was refractory to cardioversion. The patient remained hemodynamically unstable and expired after a few days. Permission for autopsy was limited to the lungs only.

## MATERIALS AND METHOD

The lungs were fixed overnight in formalin and paraffin blocks and were prepared in a routine fashion. Paraffin sections were stained with hematoxylin and eosin; selected sections were stained using the pentachrome technique and immunostained with CD31 (DAKO M0823; monoclonal-JC/70A, DAB 1:40), Factor VIII-related antigen (DAKO; polyclonal A082, 1:800) and muscle specific actin (MSA: ENZO; monoclonal C34931, 1:40). All immunostains were performed on the Ventana ES automatic immunostaining instrument after heat-induced antigen retrieval in sodium citrate buffer (pH = 6.0). Stains for acid-fast bacilli were performed using the Ziehl-Nielson technique and fungal stains were done with routine Gomori's methanamine silver stain technique.

## RESULTS

Upon macroscopic examination, the right and left lungs weighed 560 g and 520 g respectively. The surfaces were dark red-tan in the right middle and both lower lobes and light pink-tan in the right and left upper lobes. The lung surfaces were diffusely involved by 2 to 12 mm white palpable patchy areas. Cut sections showed fine 1 to 2 mm white nodules that appeared more prominently in the central areas. Also, the right middle lobe was consolidated, dark red and homogenous. The pulmonary arteries were patent with no evidence of embolism, stenosis or obstruction and the intima was yellow and smooth.

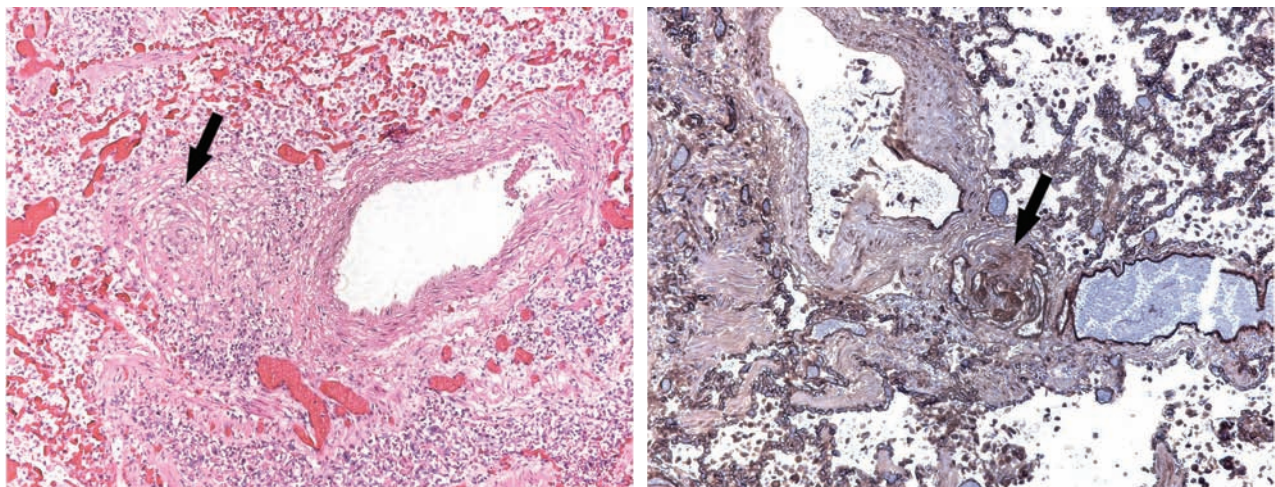


Fig. 1. (A) Perivascular granuloma encroaching upon but not destroying the vessel wall. (B) CD31 immunostain highlighting the plexiform lesion.

The microscopic evaluation revealed multiple, scattered, variably sized nonnecrotizing granulomas in a typical lymphangitic distribution - surrounding bronchioles and vessels, and beneath the pleura. The granulomas were composed of tight clusters of epithelioid histiocytes and occasional multinucleated giant cells; many were surrounded by a rim of lymphocytes. Hyalinized fibrosis was associated with some of the granulomas. The perivascular granulomas did not destroy vessel walls (Fig. 1A). Interstitial fibrosis was not a feature. The pentachrome stain confirmed that the elastic laminae of the pulmonary arteries were intact and also confirmed the absence of interstitial fibrosis. Immunostains for endothelial cells (CD31 and FVIII-related antigen) highlighted the plexiform lesions (Fig. 1B). Pentachrome, muscle-specific actin (MSA), Factor VIII-related antigen and CD31 immunostains demonstrated plexiform lesions within small to medium-sized pulmonary arteries not associated with granulomas. Occasionally, small vascular channels within the plexiform lesions contained fibrin thrombi. Some of the medium-sized vessels showed myxoid intimal proliferation and medial hypertrophy. Acid-fast bacilli or fungal elements were not seen with the special stains.

The pericardial and endomyocardial biopsies failed to show a granulomatous process.

#### DISCUSSION

Sarcoidosis is a granulomatous systemic disorder of unknown etiology. Pulmonary hypertension is an uncommon but known complication of sarcoidosis. We report a complicated and confusing case of sarcoidosis that presented as severe pulmonary hypertension. The cause remained obscure for nearly six years after the first presentation as the pulmonary hypertension was initially thought to be associated with the patient's obesity, and then later thought to be primary pulmonary hypertension. Finally, a skin biopsy performed to rule out squamous cell carcinoma revealed sarcoid granulomas. The patient was given corticosteroid treatment for two months without significant improvement in the mean pulmonary arterial pressure, although the oxygen saturation and the requirement for supplemental oxygen decreased. Ultimately the patient was started on prostacyclin infusion, which did not improve the pulmonary artery pressure but kept the patient hemodynamically stable.

Our case is unique in that the severe pulmonary hypertension was not related to either vascular destruction or interstitial fibrosis. The pulmonary hypertension in sarcoidosis is generally thought to be the result of extensive parenchymal fibrosis and vascular destruction by a granulomatous process [3, 4]. Compression of the pulmonary vessels by enlarged lymph nodes involved by granulomas and fibrosis, leading to pulmonary hypertension has also been reported [5]. Three reports by Hoffstein et al [6], Levine et al [7], and Smith et al [8] describe a destructive and fibrotic granulomatous process involving the vessel walls, but without an associated parenchymal fibrosis.

It is unclear how the granulomas are related to the pulmonary hypertension. The severe pulmonary hypertension in our case may have been caused by the

granulomas encroaching upon small to medium-sized pulmonary arteries, thereby increasing the vascular resistance resulting in increased pulmonary artery pressure. Alternatively, the granulomas themselves may be secreting cytokines and growth factors, such as vascular endothelial growth factor (VEGF) to cause plexiform lesion formation. Increased production of VEGF has been demonstrated in the epithelioid cells and multinucleated giant cells of pulmonary sarcoid granulomas [9]. Of interest, a recent publication described vascular lesions and veno-occlusion in patients with sarcoidosis and pulmonary hypertension [2], but did not find plexiform lesions in 5/5 patients nor were mechanisms suggested for the development of sarcoid-related pulmonary vasculopathy.

Other mechanisms of pulmonary hypertension associated with vascular sarcoidosis may include abnormal vascular tone [10] and major and peripheral pulmonary artery stenosis [11, 12].

Although cardiac involvement is a well-known presentation of sarcoidosis, this patient's endomyocardial and pericardial biopsies did not show granulomatous involvement. The limited autopsy precluded a complete histological examination of the heart.

Pulmonary vascular sarcoidosis without an interstitial fibrosis component needs to be considered in the differential diagnosis of severe pulmonary hypertension. The pathogenesis of pulmonary hypertension in sarcoidosis remains to be determined, but plexiform lesion formation can occur.

*Acknowledgment:* This work was supported in part by the K08 HL03911-04.

#### REFERENCES

1. Efferen L. The challenge of sarcoidosis. *Chest*. 2001; 120(3): 697-698.
2. Nunes H, Humbert M, Capron F, Brauner M, Sitbon O, Battesti J-P, Simonneau G, Valeyre D. Pulmonary Hypertension Associated With Sarcoidosis: Mechanisms, Hemodynamics, and Prognosis. *Thorax*. 2005; (Epub ahead of print).
3. Davies J, Goodwin JF, Nellen M. Reversible pulmonary hypertension in sarcoidosis. *Postgrad Med J*. 1982;58: 282-285.
4. Systemic diseases involving the lung. In: Katzenstein and Askin. *Surgical pathology of non-neoplastic lung disease*. Philadelphia, phil: W. B Saunders, 1997: 179-185.
5. Battesti JP, Georges R, Basset F, et al. Chronic cor pulmonale in pulmonary sarcoidosis. *Thorax*. 1978; 33: 76-84.
6. Hoffstein V, Ranganathan N, Mullen JBM. Sarcoidosis simulating pulmonary veno-occlusive disease. *Am Rev Respir Dis*. 1986; 134: 809-811.
7. Levine BW, Saldana M, Hutter AM. Pulmonary hypertension in sarcoidosis-A case report of rare but potentially treatable cause. *Am Rev Respir Dis*. 1971; 103: 413-417.
8. Smith LJ, Lawrence JB, Katzenstein AA. Vascular sarcoidosis: a rare cause of pulmonary hypertension. *Am J Med Sci*. 1983; 285(1):38-44.
9. Tolnay E, Kuhnen C, Voss B, et al. Expression and localization of vascular endothelial growth factor and its receptor flt in pulmonary sarcoidosis. *Virchows Arch*. 1998; 432: 61-65.

10. Barst RJ, Ratner SJ. Sarcoidosis and reactive pulmonary hypertension. Arch Intern Med. 1985; 145: 2112-2114.
11. Damuth TE, Bower JS, Cho K, et al. Major pulmonary artery stenosis causing pulmonary hypertension in sarcoidosis. Chest. 1980; 78: 888-891.
12. Mangla et al. Sarcoidosis, pulmonary hypertension and acquired peripheral pulmonary artery stenosis. Cathet Cardiovasc Diagn. 1985; 11: 69-74.

*Received: December 5, 2005 / Accepted: January 17, 2006*

*Address for correspondence:*

Carlyne D. Cool, M.D.  
Box 216, Department of Pathology  
University of Colorado Health Science Center  
4200, E. Ninth Avenue  
Denver, CO 80262  
USA  
Tel. #: 011-1- (303)-315-6228  
Fax #: 011-1- (303)-315-4792 (Surgical Pathology)  
E-mail: carlyne.cool@uchsc.edu