

BRUNS SYNDROME CAUSED BY INTRAVENTRICULAR TUMOR

M. Krasnianski¹, T. Müller¹, K. Stock², S. Zierz¹

Departments of Neurology¹ and Radiology², Martin-Luther-University Halle-Wittenberg, Germany

Abstract

The Bruns syndrome is an unusual phenomenon, characterized by attacks of sudden and severe headache, vomiting and vertigo, triggered by abrupt movement of the head. The presumptive cause of the Bruns syndrome is a mobile deformable intraventricular lesion leading to an episodic obstructive hydrocephalus resulted from an intermittent or positional CSF obstruction with elevation of intracranial pressure due to a ball-valve mechanism. Although the old neurological literature recognized tumors as well as neurocysticercosis as causes of the Bruns syndrome, during the last 60 years only intraventricular neurocysticercosis was reported to cause this symptom-complex. Here, we report a 38-year-old woman with relapsing attacks of headache, vertigo, nausea, vomiting, and ataxia provoked by head rotation corresponding to the classical Bruns syndrome. The cranial MRI revealed a tumor in the third ventricle and a further tumor in the fourth ventricle, which could cause a transient obstruction of the CSF pathways. This unusual observation of the Bruns syndrome in a non-parasitary disease of the CNS adds the syndrome to the differential diagnosis of paroxysmal vertigo.

Key words: Bruns syndrome; intraventricular brain tumor

INTRODUCTION

The Bruns syndrome is an unusual phenomenon characterized by attacks of severe headache, vomiting and vertigo, triggered by abrupt movement of the head [1]. The syndrome was first-time reported in 1902 by Ludwig Bruns (1858-1916) from Hannover (Germany). The supposable cause of the Bruns syndrome is a mobile deformable intraventricular lesion leading to an episodic non-communicating hydrocephalus resulted from an intermittent or positional CSF obstruction with elevation of intracranial pressure due to a ball-valve mechanism [2]. In some cases an abrupt permanent obstruction of the CSF flow occurs, which causes acute hydrocephalus leading to stupor, coma and death due to brain herniation [2]. The intraventricular neurocysticercosis was reported by Bruns as well as by subsequent publications as the cause of this symptom-complex [1, 2, 3]. Here, we report a patient with the classical Bruns syndrome caused by an intraventricular tumor verified on MRI. Although the old neurological literature recognized tumors as well as neurocysticercosis

as causes of the Bruns syndrome, in the modern literature only cysticercosis was reported to cause this symptom-complex [2, 3, 4]. Our case is a first report of the Bruns syndrome in a non-parasitary disease of the CNS since 60 years.

CASE REPORT

A 38-year-woman was referred with attacks of severe, throbbing, holocephalic headache accompanied by non-systemic vertigo, nausea, vomiting, and ataxia, which were provoked by head rotation. During the last year she had four such attacks, lasting from 5 to 30 minutes. On the first hospital day, one attack with all above mentioned symptoms and a spontaneous rotatory nystagmus lasting about five minutes could be seen.

On admission, she was alert and oriented. She had a slight paresis of the left rectus superior muscle without diplopia, and a mild bilateral ptosis (more of the left eye). Pupil reaction to light was normal. The patient had no nystagmus, and no Horner's syndrome. The fundoscopic examination revealed no papilloedema. Speech, soft palate movements, swallowing, gag reflex, cough reflex, and tongue movements were normal. There was no disturbance of facial movement and sensation, and no disturbances of trapezius and sternocleidomastoid muscles. The patient had no paresis. The deep tendon reflexes were normal, and she had no Babinski response. No ataxia was observed. Perception was normal.

Brain MRI performed on the second hospital day revealed a larger mass lesion in the quadrigeminal lamina and a smaller mass lesion in the fourth ventricle (Figs. 1-3). The patient rejected further diagnostic tests and was discharged from the hospital. No follow-up information was available.

DISCUSSION

The constellation of signs and symptoms in our patient corresponded to the classical Bruns syndrome. This was first described in 1902 by Ludwig Bruns, who reported periodic attacks of violent headache, vomiting and great vertigo with changes of head posture in a man with a cysticercus of the fourth ventricle [1]. The patient was in comparatively good health between attacks. He had merely to avoid turning his head quickly, since any sudden rotation, especially to the left, brought on vertigo and nausea, and might even

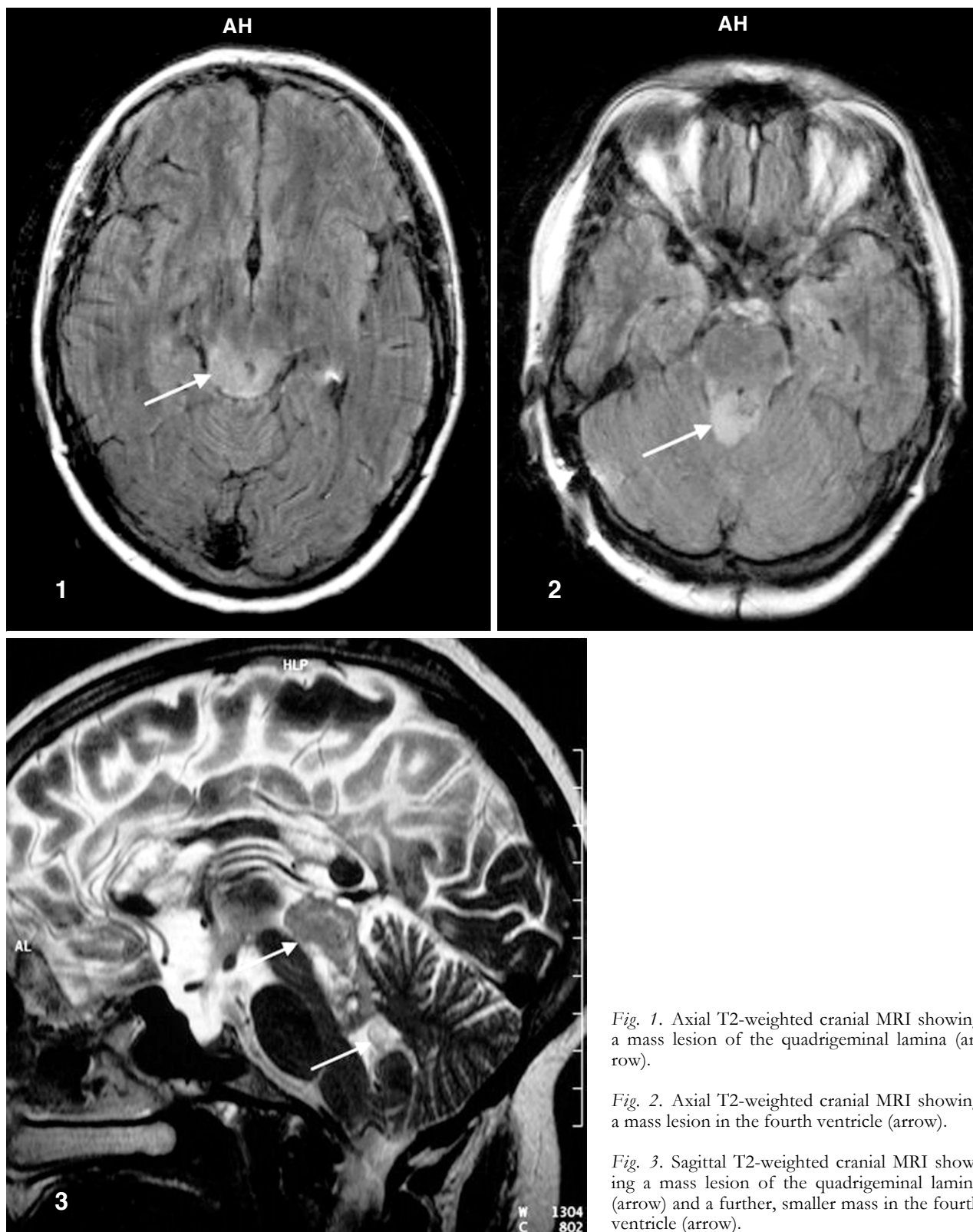


Fig. 1. Axial T2-weighted cranial MRI showing a mass lesion of the quadrigeminal lamina (arrow).

Fig. 2. Axial T2-weighted cranial MRI showing a mass lesion in the fourth ventricle (arrow).

Fig. 3. Sagittal T2-weighted cranial MRI showing a mass lesion of the quadrigeminal lamina (arrow) and a further, smaller mass in the fourth ventricle (arrow).

cause him to fall down [1]. Oppenheim gave the name “Bruns syndrome” to this clinical complex and this designation has been continued in the literature [5]. Bruns emphasized two important aspects of the syndrome: the development of attacks on change of posture of the head and a freedom from symptoms between the attacks [1].

The pathomechanism of the Bruns syndrome is not clear. Bruns believed the symptoms resulted from a change in position of the cyst in the fourth ventricle with periodic blocking off of the ventricular system on change of head posture. He admitted later that a fixed cyst or even tumor might produce the symptoms but he still invoked the mechanism of intermitted hy-

drocephalus through blockade of the ventricular system to explain the symptom-complex [6]. Although this explanation may be true for a freely movable cyst within the fourth ventricle, it fails to explain the cases resulting from brain tumors and offers no explanation for the head posture. According Marburg [7] and Alpers and Yaskin [4], there is much in the symptomatology of the Bruns syndrome to suggest irritation of the vestibular nuclei or their pathways. Marburg speculated that the symptoms of this syndrome are in reality vestibular attacks precipitated by a sudden change of position [7].

Also in our patient the mechanism of the Bruns syndrome is not entirely clear. The attacks could result from the transient obstruction of the aqueduct by the tumor of the quadrigeminal lamina as well as from possible positional irritation of the vestibular nuclei and their pathways by the smaller tumor in the fourth ventricle (Figure 1-3). The nature of the infiltrative tumor in our patient remains open, but the absent Gadolinium enhancement on MRI is compatible with a benign tumor.

During the last 60 years, the Bruns syndrome was reported only in patients with intraventricular cysticercosis, which come from regions where this disease is endemic, including Central and South America, Asia and Africa [2, 3]. Although older authors found the Bruns syndrome also with tumors of the midline in the cerebellum as well as with tumors of third and lateral ventricles [4, 7], for modern neurologists, who are familiar with this rare phenomenon, the symptom-complex is closely associated with cerebral cysticercosis. This unusual observation of the Bruns syndrome in a non-parasitary disease of the CNS in a European patient adds the syndrome to the differential diagnosis of paroxysmal vertigo.

REFERENCES

1. Bruns L. Neuropathologische Demonstrationen. Neurol Centralbl. 1902; 21: 561-567.
2. Torres-Corzo J, Rodriguez-Della Vecchia R, Ranger-Castilla L. Bruns syndrome caused by intraventricular neurocysticercosis treated using flexible endoscopy. J Neurosurg. 2006; 104: 746-748.
3. Jimenez Caballero PE, Mollejo Villanueva M, Marsal Alonso C, Alvares Tejerina. A. Síndrome de Bruns: descripción de un caso de neurocysticercosis con estudio anatomopatológico. Neurología. 2005; 20: 86-89.
4. Alpers BJ, Yaskin HE. The Bruns syndrome. J Nerv Ment Dis. 1944; 100: 115-134.
5. Oppenheim H. Lehrbuch der Nervenkrankheiten. 7. Auflage. Berlin: Karger, 1923: 1503.
6. Bruns L. Neuropathologische Demonstrationen. Neurol Centralbl. 1906; 25: 540-544.
7. Marburg O. Die Tumoren im IV Ventrikel. In: Alexander G, Marburg O, eds. Handbuch der Neurologie des Ohres. Band 3. Wien: Urban und Schwarzenberg, 1926: 116.

Received: March 1, 2007 / Accepted: August 9, 2007

Address for correspondence:

Michael Krasnianski, MD
 Klinik für Neurologie
 Martin-Luther-Universität Halle-Wittenberg
 Ernst-Grube-Str. 40
 06120 Halle (Saale)
 Germany
 Tel.: +49-345/557 2858
 Fax: +49-345/557 2020
 e-mail: michael.krasnianski.neurologie@medizin.uni-halle.de