

INGUINAL HERNIA VS. ARTHRITIS OF THE HIP IN SPORTING ADOLESCENTS

CASE REPORT AND REVIEW OF THE LITERATURE

R. G. Holzheimer, U. Gresser

Department of Surgery and Rheumatology, Praxisklinik Sauerlach, Germany

Abstract

Chronic pain in the hip, groin or thigh can be caused by a wide spectrum of diseases posing extended diagnostic problems. We describe the case of a 10-years old child with chronic pain in the groin with gait restriction for more than six months without successful classification and treatment.

The girl suffered from heavy pain in the groin after a sporting contest which forced her to walk with walking sticks and to avoid climbing stairs. Within six months she was examined by pediatric, orthopedic, pediatric surgery, pediatric orthopedic, radiology, pediatric rheumatology specialists. Working diagnoses were transient synovitis (coxitis fugax), arthritis, streptococcal arthritis, Morbus Perthes, rheumatic fever, rheumatoid arthritis. She was treated with antibiotics and ibuprofen in high dosage. Repeated laboratory tests and imaging studies (ultrasound, x-rays, magnetic resonance imaging) of the hip and pelvis did not support any of these diagnoses.

Six months after beginning of the complaints the girl was presented by her mother to our institution. The physical examination showed a sharp localized pain in the groin, just in the region of the inguinal ligament with otherwise free hip movement. There was no visible inguinal hernia. The family history for hernia was positive. After infiltration of the ilioinguinal nerve the girl had a complete long-lasting disappearance of pain and gait disturbance. This led to the diagnosis of inguinal hernia with nerve entrapment. After hernia repair and neurectomy/neurolysis there was a continuous state of disappearance of pain and gait disturbances.

Conclusion: To avoid such a diagnostic dilemma one should always discuss all possible causes. Non-visible inguinal hernia may be more common in females than previously thought. Nerve entrapment as a cause of groin pain has been well described. The relationship of the start of complaints with sporting activity, a positive family history for inguinal hernia, a lack of signs of inflammation and bone involvement in the laboratory and imaging studies together with a localized pain in the groin, almost immediate long-lasting disappearance of pain after infiltration of the ilioinguinal nerve allowing free motion leads to the diagnosis of inguinal hernia with nerve entrapment. Hernia repair and neurolysis are the adequate treatment avoiding unnecessary radiation.

INTRODUCTION:

Chronic pain in the hip, groin or thigh of a child may have a deep impact on the life of that child and the whole family. In most instances a defect of the musculoskeletal system may be the underlying mechanism – non-rheumatic or rheumatic (Junnila and Cartwright 2006). The most common hip joint diseases in children are transient synovitis (Coxitis fugax), rheumatoid arthritis, osteomyelitis, Legg-Perthes disease, slipped capital femoral epiphysis, dysplasia and tumors (Hackenbruch et al. 1978). However, other defects, e.g., inguinal hernia and nerve entrapment, can cause pain and consecutive disturbances of the gait.

We describe a case of chronic pain in hip, groin and thigh with gait restriction in a 10 years old female child.

CASE REPORT

A 10 years old female child had a sharp pain in the right groin for the first time during a sport contest (Bundesjugendspiele July 2006) after a throwing competition. Within the next six months this child was presented to 12 different doctors (Table 1) and was examined by repeated blood tests, x-rays, ultrasound and magnetic resonance tomography (MRT) (Table 2).

Five days after the pain started she was presented to a pediatrician who diagnosed coxitis fugax and prescribed bed rest. The pain in the groin was of changing intensity during the day ranging from 3-7 of the visual analog scale (VAS). During the night the girl sometimes awoke due to a sharp heavy pain (10 at the VAS). Two days later a pediatric surgeon who was consulted for persisting pain examined the inguinal and hip region and also recommended bed rest for **coxitis fugax**. A week later the girl had another appointment with the pediatrician and was sent to an orthopedic doctor who suggested it may be an **inguinal strain** with **Morbus Perthes** and **arthritis** as differential diagnosis and sent her to a pediatric surgery department. Another week later she had an examination of the hip and inguinal region in this pediatric surgery department, further tests (bacteriologic examination of a throat swab, stool and urine culture, eye examination) were done and a treatment for **streptococcal arthritis** was started. Another two weeks later – due to continuing pain – the girl had an appointment with a second

Table 1. Follow-up of the 10 years old female patient after first heavy pain during a sport contest Jul 13th 2006 – June 2007

Time	Doctor	Specialty	Diagnosis	Treatment
Jul 06	A	Pediatrics	Coxitis fugax	-
Jul 06	B	Pediatric Surgery	Coxitis fugax	Bed rest
Jul 06	A	Pediatrics	No new diagnosis	Referral to Orthopedics
Jul 06	C	Orthopedics	Inguinal strain arthralgia DD Perthes	Referral to pediatric surgery
Aug 06	D	Pediatric surgery	Streptococcal arthritis	Antibiotics Urine exam Stool exam Throat swab Eye exam
Aug 06	E	Pediatrics	DD Perthes	Referral to radiology for MRT
Aug 06	F	Radiology	Coxitis fugax DD Rheumatic fever, streptococcal infection	Control MRT in 3-4 weeks
Sep 06	G	Orthopedics	Coxalgia	Repeat MRT
Sep 06	H	Radiology	No pathology demonstrated	-
Sep 06	B	Pediatric surgery	No new diagnosis	Referral to pediatric orthopedics
Sep 06	I	Pediatric orthopedics	Coxitis fugax, DD rheumatoid arthritis	Iontophoresis
Oct 06	G	Orthopedics	No new diagnosis	Referral to pediatric surgery
Oct 06	D	Pediatric surgery	Recurrent hip pain	Ibuprofen 2x200 mg daily Referral to pediatric rheumatology
Nov 06	J	Pediatric rheumatology	DD Enthesiopathy Reactive arthritis Juvenile idiopathic arthritis Perthes	Ibuprofen 3x200 mg daily Physiotherapy Referral to radiology for MRT
Nov 06	K	Radiology	No Perthes and no sacroiliitis	-
Jan 07	L	Hernia Surgery Clinic	Inguinal hernia with ilioinguinal entrapment	Herniotomy with neurolysis Since then free of complaints

DD = differential diagnosis; MRT = magnetic resonance tomography

pediatric doctor who sent her to a radiologist for a magnetic resonance imaging (MRT) of the hip and pelvis. The radiologist described a discrete effusion in the hip joint and suggested it may be **coxitis fugax** or **rheumatic fever**. However, the antibiotic treatment combined with ibuprofen 2x200 mg did not relief the pain. In September 2006 further examination followed by another orthopedic doctor and another MRT was done at a different radiological institution. The first pediatric surgeon reexamined the patient. He sent the young girl to the pediatric orthopedic university department. September 2006 specialists of the pediatric orthopedic university department diagnosed **coxitis fugax**, differential diagnosis **rheumatoid arthritis**. In the meantime the ten year old girl could barely walk without walkingsticks and was almost unable to climb stairs due to pain in the groin during flexion of the hip joint. In October 2006 another appointment followed with one of the orthopedic doctors and the girl was sent another time to the pediatric surgery department without any new evidence. In November 2006 the girl was then transferred to a children rheumatic center where she was examined, further laboratory tests were done, and an ultrasound examination of the hip joints performed. In the family history it was rec-

ognized that the brother of the mother had psoriasis and Crohn's disease, which was diagnosed also in the father of the mother. All tests were negative and another MRI was requested to exclude other diseases, e.g., **Morbus Perthes**. The MRT did not reveal any pathologic alteration. The doctors asked her to continue ibuprofen 3x200 mg and recommended physiotherapy. In January 2007 a physiotherapist supposed a **strain of the inguinal ligament** and recommended an examination at our institution which is specialized on hernia, sports injury and rheumatology.

The young girl came with walking sticks unable to climb the stairs. She complained of heavy pain in the right groin. The range of motion in the hip was not limited, but there was heavy pain in the inguinal region with a maximum just above the inguinal ligament. The sonographic evaluation of the right groin showed a defect of the posterior floor of the inguinal canal when compared to the left side. Infiltration therapy of the ilioinguinal nerve resulted in almost immediate relief of pain, which lasted for more than 12 hours and allowed the child to walk without sticks, even on the stairs. There was a positive family history for congenital inguinal hernia: the grandfather (father of the mother), the mother, the brother of the mother and a

Table 2. Laboratory, ultrasound, x-rays and MRT tests in a ten years old female patient with hip-, groin- and thigh-pain.

Time	Doctor	Lab-test	Ultrasound	X-ray	MRT
Jul 06	C		Both hip joints without effusion or inflammatory reaction	Hip, pelvis: no sign of Perthes or Epiphysiolysis	
Aug 06	D	L 6200 CRP 0,1 mg/dl Sedimentation 2 (first hour) Blood count normal <u>Differential blood count</u> Neutrophils 46% Eosinophils 3% Basophils 1% Lymphocytes 42% Monocytes 5% RF < 7.5 kU/L (norm <14) ASL 891 kU/L (norm <320) Electrolytes normal CK,Creatinine,Urea, Borrelia IgG-Ab, IgM-Ab, ANA, pANCA, cANCA, ANCA IgG all normal	Both hip joints without effusion or inflammatory reaction		
Aug 06	F				Pelvis and hips: Bone structures normal, no sign of epiphysiolysis, minimal hip joint effusion right, no periarticular edema
Sep 06	H				Right hip joint: Normal bone and joint structure; no effusion; no hernia
Sep 06	I		Both hip joints without effusion or inflammatory reaction		
Oct 06	D		Both hip joints without effusion or inflammatory reaction	Right hip joint no sign of Perthes, normal	
Oct 06	G		Both hip joints without effusion or inflammatory reaction	Right hip joint no sign of Perthes, normal	
Nov 06	J	Hb 11,9 g% L 5,200/_l Thr 252,000/_l Sedimentation 4/9 mm/h CRP 0.1 mg/dl ANA 1:80 RF negative HLA-B27 negative ASL 608 IU/ml (slightly elevated) CK 170 U/l (normal 154 U/l) GOT,GPT, GGT,AP,Immunoglobulins,Creatinine Urea all normal	Both hip joints without effusion or inflammatory reaction		
Nov 06	K				Hip joints and pelvis: bone structure normal, no sign of effusion, soft tissue of the hip normal

Table 3. Signs and symptoms pathbreaking for diagnosis and successful treatment of our patient.

- Start of the complaints related to sporting activity
 - Positive family history for hernia
 - No signs of inflammation in the laboratory investigations
 - No signs of bone involvement in several imaging techniques
 - No limited motion in the hip, but sharp localized pain in the groin
 - Almost immediate, long-lasting disappearance of pain allowing walking without sticks, even on stairs, after the infiltration of the ilioinguinal nerve
- and finally
- complete resolution of pain and walking difficulties after surgical hernia repair with neurolysis of the nerve

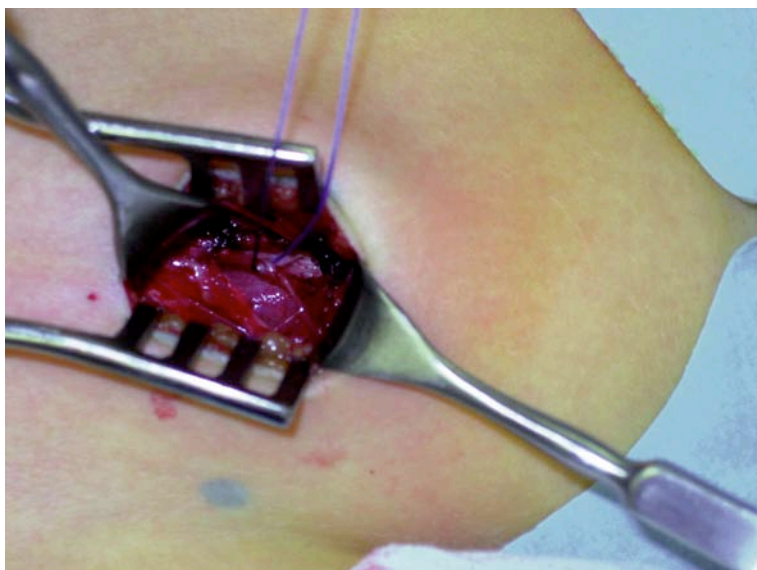


Fig. 1. Right groin with the hypertrophic ilioinguinal nerve entrapped in the obliquus externus fascia.

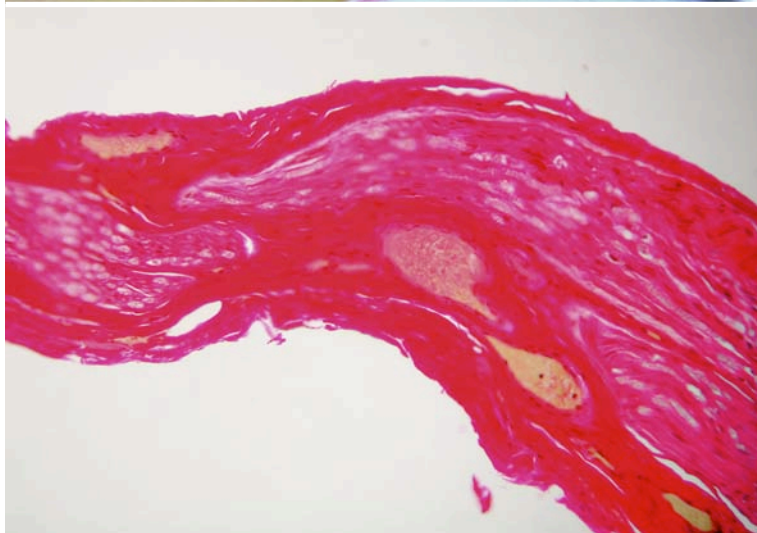


Fig. 2. Histological microscopical section of the fibrotic ilioinguinal nerve.

sister of the girl all had an inguinal hernia repair during their childhood. Based on the family history, the personal past history, the physical and ultrasound examination and the results of the infiltration therapy the diagnosis of an **inguinal hernia with nerve entrapment** was inevitable (Table 3). Intraoperatively (29.1.2007) the defect of the posterior floor and the nerve entrapment was verified. The ilioinguinal nerve was caught in the externus aponeurosis and bend in a

90° angle (Fig. 1). The ligamentum rotundum was fixed to the inguinal ligament and the neurolysis was followed by a nerve resection. The histological evaluation of the nerve demonstrated a fibrosis of the nerve tissue (Fig. 2). The postoperative follow-up was uneventful – the girl was free of complaints. Immediately after surgical treatment the girl could walk and climb stairs again without walking sticks and pain, and is now completely free of pain for more than four

months.

DISCUSSION

Children and adolescents with complaints in the hip, groin and/or thigh are often considered to have a disease of rheumatic or nonrheumatic origin involving orthopedic or rheumatic doctors.

Nonrheumatic causes of musculoskeletal pain including sprains and strains, patellofemoral syndrome, stress fractures, and osteochondrosis are much more common than rheumatic causes. In case of a characteristic skin rash the arthritis may be due to dermatomyositis or without rash it can be caused by an inherited disease, e.g., hemophilia or sickle cell disease (Junnila and Cartwright 2006).

Rare causes of musculoskeletal pain in children are infections or tumors including osteomyelitis, psoas abscess, bone sarcoma or osteoid osteoma (Longis et al. 1988; Shinbar et al. 1996; Kim et al. 1999; Sherry and Malleson 2002; Wurtz et al. 2002).

None of these diseases are likely according to the first examinations of this child in July/August 2006.

Katz (2006) recommended that every child presenting with a complaint of the hip, thigh or knee must undergo a hip examination to excluded slipped capital femoral epiphysis. Avascular femoral head necrosis or apophyseal avulsion may be other causes (Zacher and Gursche 2003). Legg-Calve-Perthes disease, an idiopathic avascular necrosis during childhood, which has been considered in the differential diagnosis in this child, is best demonstrated by MRT or sonography (Bosch et al. 1998; Kramer et al. 2002). The most common hip disease in childhood with unknown etiology is coxitis fugax. Radiologic findings and serological testing are unspecific. Sonographic examination is of great value (Bernd et al. 1992; Bosch et al. 1998; Mumme et al. 2005).

Rheumatic causes include rheumatic fever or streptococcal infection-related arthritis, juvenile rheumatoid arthritis, arthritis with enthesitis, and reactive arthritis (Junnila and Cartwright 2006). Enteric organisms are known to trigger reactive arthritis, which has been one of the working diagnoses in this child. The enthesitis-related arthritis (ERA) form of juvenile idiopathic arthritis (JIA) clinically resembles reactive arthritis (Saxona et al. 2006). Poststreptococcal reactive arthritis (PSRA) clinical presentation is heterogeneous and different from that of acute rheumatic fever (ARV) and from that of HLA B27-associated reactive arthritis (Mackie and Keat 2004). There has been no sign of previous infection in this child according to the patient's history and the information obtained from the mother of the patient. The association between arthritis and streptococcal disease is not unanimously accepted (Mackie and Keat 2004). Also the laboratory results did not support the diagnosis of a rheumatic disease. It should not be forgotten that always the articular versus nonarticular site of origin should be distinguished. "The musculoskeletal evaluation must discriminate the anatomic site(s) of origin of the patient's complaint ... Nonarticular (or periarticular) structures, such as supportive extraarticular ligaments, tendons, bursae, muscle, fascia, bone, nerve, and overlying skin, may be involved in the pathologic process. Pain from

these structures may mimic true articular pain because of their proximity to the joint. Distinguishing between articular and nonarticular disease requires a careful and detailed examination." (Cush and Lipsky 1998).

Other causes of chronic pain may be related to reproductive organs, urological or gastrointestinal diseases (Carter 1998). Ovarian torsion in the female may be associated with intermittent episodes of groin and thigh pain (Merriman and Auldism 2000; Kienstra and Ward 2002). An aneurysm of the femoral artery may manifest as an acute pain (Rainio et al. 2003).

Lipomas of the cord and round ligament occur quite often and can cause hernia-type symptoms in the absence of a true hernia. They should be considered in patients with normal examination results and groin pain. Unfortunately they can be overlooked during laparoscopic procedures (Lilly and Arregui 2002).

It is well recognized that a positive family history is a risk factor for inguinal hernia (Liem et al. 1997). Inguinal hernia in female patients may be non-visible and non-palpable (Spangen et al. 1988), but dull inguinal pain, intermittent neuralgic pain and a pinprick hyperalgesia of the skin corresponding to the ilioinguinal nerve and a distinct tenderness upon palpation over the deep inguinal ring were described as leading symptoms of inguinal hernia in female patients (Spangen et al. 1988). Herrington (1975) has reported an incidence of 8% for the repair of occult hernias; however, the true incidence of occult hernias in the female may be much higher. Although ultrasound examination may be helpful in establishing the diagnosis (Bradley et al. 2006) this may not be true in every case (Alam et al. 2005). The experience of the ultrasound examiner is influenced by the intraoperative confirmation of the preoperative diagnosis. Peritoneography or CT-performed post-herniography may be an alternative in some countries; they are, however, seldomly used (Heise et al. 2002; Markos and Brown 2005). Entrapment neuropathy of the ilioinguinal nerve, which has been demonstrated intraoperatively in this child, is a relevant diagnosis of inguinal pain (Schorl et al. 2002). The nontraumatic compression syndrome of the ilioinguinal nerve or ilioinguinalis syndrome is known to cause pain in the groin and painful restriction of rotation and extension of the hip joint. Therapy usually consists of operative neurolysis and neurectomy (Kopell and Thompson 1963; Mummenthaler et al. 1998; Deysine et al. 2002). The relationship of sports activity to nerve entrapment has been well described (Ziprin et al. 1999; Holzheimer 2005).

CONCLUSION

To avoid such a diagnostic dilemma one should always discuss all possible causes. Non-visible inguinal hernia may be more common in females than previously thought. Nerve entrapment as a cause of pain in the athlete has been well described. The relationship of the start of complaints with sporting activity, a positive family history for inguinal hernia, a lack of signs of inflammation and bone involvement in the laboratory and imaging studies together with a localized pain in the groin, almost immediate longlasting disappear-

ance of pain after infiltration of the ilioinguinal nerve allowing free motion leads to the diagnosis of inguinal hernia with nerve entrapment. Hernia repair and neurectomy are the adequate treatment of choice avoiding unnecessary radiation.

REFERENCES

- Alam A, Nice C, Uberoi R. The accuracy of ultrasound in the diagnosis of clinically occult groin hernias in adults. *Eur J Radiol* 2005;15(12):2457-61
- Bernd L, Niethard FU, Graf J, Kaps HP. Transient hip joint inflammation (coxitis fugax). *Z Orthop Ihre Grenzgeb* 1992;130(6):529-35
- Bosch R, Niedermeier C, Heimkes B. Value of ultrasound in differential diagnosis of pediatric hip joint effusion (Perthes disease, C. fugax, epiphysiolysis capitis femoris). *Z Orthop Ihre Grenzgeb* 1998;136(5):412-9
- Bradley M, Morgan J, Penlow B, Roe A. The positive predictive value of diagnostic ultrasound for occult herniae. *Ann R Coll Surg Engl* 2006;88(2):165-7
- Carter JE. Surgical treatment of chronic pelvic pain. *JLS* 1998;2(2):129-139
- Cush JJ, Lipsky PE. Approach to articular and musculoskeletal disorders. In: Fauci AS, Braunwald E, Isselbacher KJ et al. (eds). *Harrison's Principles of Internal Medicine*, 14th edition, McGraw-Hill 1998, pp1928-1929
- Deysine M, Deysine GR, Roed WP. Groin pain in the absence of hernia: a new syndrome. *Hernia* 2002;6(2):64-7
- Hackenbruch W, von Gumpenberg S, Karpf PM. Juvenile hip pain. 2. Femur head epiphysiolysis, hip dysplasia, tumors. *Fortschr Med* 1978;96(42):2132-6
- Heise CP, Sproat IA, Starling JR. Peritoneography (herniography) for detecting occult inguinal hernia in patients with inguinodynia. *Ann Surg* 2002;235(1):140-4
- Herrington JK. Occult inguinal hernia in the female. *Ann Surg* 1975;181(4):481-3
- Holzheimer RG. Inguinal hernia: classification, diagnosis and treatment – classic, traumatic and Sportsman's hernia. *Eur J Med Res* 2005;10(3):121-134
- Junnila JL, Cartwright VW. Chronic musculoskeletal pain in children: Part II. Rheumatic causes. *Am Fam Physician* 2006;74:293-300
- Katz DA. Slipped capital femoral epiphysis: the importance of early diagnosis. *Pediatr Ann* 2006;35(2):102-11
- Kienstra AJ, Ward MA. Third place winner. Three-year old female with intermittent ovarian torsion. *J Emerg Med* 2002;23(4):375-7
- Kim NH, Lee HM, Yoo JD, Suh JS. Sacroiliac joint tuberculosis. Classification and treatment. *Clin Orthop Relat Res* 1999;358:215-22
- Kopell HP, Thompson WAL. *Peripheral entrapment neuropathies*. Williams and Wilkins Baltimore 1963
- Kramer J, Hofmann S, Scheurecker A, Tschauner C. Perthes disease. *Radiologe* 2002;42(6):432-9
- Liem MSL, van der Graaf Y, Zwart RC, Geurts I, van Vroonhoven TJMV. Risk factors for inguinal hernia in women: a case-control study. *Am J Epidemiol* 1997;146:721-6
- Lilly MC, Arregui ME. Lipomas of the cord and round ligament. *Ann Surg* 2002;235(4):586-590
- Longis B, Monilès D, Robert M, Valette C, Mechin JF, Alain JL. Osteoid osteoma of the femur neck in children and adolescents. Apropos of 12 cases. *Chir Pediatr* 1988;29(1):24-8
- Mackie SL, Keat A. Poststreptococcal reactive arthritis: what is it and how do we know? *Rheumatology (Oxford)* 2004;43(8):949-54
- Markos V, Brown EF. CT herniography in the diagnosis of occult groin hernias. *Clin Radiol* 2005;60(2):251-6
- Merriman TE, Auldist AW. Ovarian torsion in inguinal hernias. *Pediatr Surg Int* 2000;16(5-6):383-5
- Mumme T, Berkemeier E, Maus U, Bauer A, Wirtz DC. Coxitis fugax – the beginning of Perthes' disease? *Z Orthop Ihre Grenzgeb* 2005 143(5):529-33
- Mummenthaler M, Schliack H, Stöhr M. *Läsionen peripherer Nerven und radikuläre Syndrome*. Georg Thieme Verlag Stuttgart 1968
- Rainio P, Biancari F, Leinonen S, Juvonen T. Aneurysm of the profunda femoris artery manifested as acute groin pain in a child. *J Pediatr Surg* 2003;38(11):1699-700
- Saxena N, Misra R, Ayyarwal A. Is the enthesitis-related arthritis subtype of juvenile idiopathic arthritis a form of chronic reactive arthritis? *Rheumatology (Oxford)* 2006;49(9):1129-32
- Schorl M, Schweikardt B, Kaminski M. Idiopathic entrapment neuropathy of the ilioinguinal nerve – a differential diagnosis in inguinal pain. *Schweiz Rundsch Med Prax* 2000;89(5):197-200
- Sherry DD, Malleson PN. The idiopathic musculoskeletal pain syndromes in childhood. *Rheum Dis Clin North Am* 2002;28:669-85
- Shinhar D, Mares AJ, Finaly R, Cohen Z, Barki Y. Psoas abscess: diagnostic dilemma in childhood. *Harefuah* 1996;131(10):402-4
- Spangen L, Andersson R, Ohlsson L. Non-palpable inguinal hernia in the female. *Am Surg* 1988;54(9):574-7
- Wurtz LD, Peabody TD, Simon MA. Delay in the diagnosis and treatment of primary bone sarcoma of the pelvis. *J Bone Joint Surg Am* 1999;81(3):317-25
- Zacher J, Gursche A. Regional musculoskeletal conditions: hip pain. *Best Pract Res Clin Rheumatol* 2003;17(1):71-85
- Ziprin P, Williams P, Foster ME. External oblique aponeurosis nerve entrapment as a cause of groin pain in the athlete. *Br J Surg* 1999;86(4):566-8

Received: Received: May 7, 2007 / Accepted: June 5, 2007

Address for correspondence:

Prof. Dr. med. René G. Holzheimer
Surgeon, Sportsmedicine
Prof. Dr.med. Ursula Gresser
Internal Medicine, Rheumatology
Praxisklinik Sauerlach
Tegernseer Landstr. 8
82054 Sauerlach
Germany
Tel.: +49-8104-668454
Fax: +49-8104.668453