

SPONTANEOUS REGRESSION OF RETINAL ANGIOMATOUS LESIONS IN V. HIPPEL-LINDAU DISEASE (VHL)

D. Schmidt¹, H. P. H. Neumann²

¹Augenklinik, ²MedizinischeKlinik, University Freiburg i. Br., Germany

Abstract

Background: Very little documentation of spontaneous regression of an angiomatous retinal lesion in v. Hippel-Lindau disease (VHL) exists. It is commonly believed that a spontaneous change of hemangiomas into fibrotic lesions occurred.

Patients/Methods: Follow-up examinations of four patients with VHL in the Freiburg VHL study were carried out.

Results: A 16-year-old girl revealed a vascular lesion at the border of the optic disc. Control examination nine years later revealed complete spontaneous regression of the retinal vascular changes. A slight retinal vascular change at the superior border in her right eye was found in a 36-year-old woman. A control examination 20 years later revealed regression of the lesion. A 41-year-old woman showed in the retinal periphery a small fibrotic white hemangioma with a pigmented feeder vessel as sign of spontaneous tumor regression. A 12-year-old boy had a retinal microaneurysm inferior to the optic disc that disappeared several years later.

Conclusion: Documentations of spontaneous regression of minor angiomatous retinal lesions in VHL exist. Such vascular changes are rare. Every retinal lesion should be controlled by follow-up examination and documentation. In case of retinal lesion growth, treatment is necessary.

Key words: v. Hippel-Lindau disease, retinal vascular lesion, fibrotic hemangioma, microaneurysm

INTRODUCTION

A definite regression of angiomatous retinal changes in v. Hippel-Lindau disease (VHL) has not been documented in the literature. We describe retinal changes in four patients with VHL that disappeared spontaneously several years later.

CASE HISTORIES

1. A 16-year-old girl with VHL revealed a vascular anomaly and circumscribed retinal edema at the nasal border of the optic disk in her left eye in 1992 (Fig. 1 a). Her mother, sister and brother also showed retinal changes due to v. Hippel-Lindau's disease. The moth-

er had undergone surgery because of a pheochromocytoma.

The 16-year-old patient revealed a small hemangioma far in the superior outer periphery of the retina. A control examination in 1996 showed that the small peripheral hemangioma was slightly enlarged. Argon laser coagulation was then carried out. In 1997, examination revealed that the small tumor had been completely destroyed. Her visual acuity remained 20/20. Nine years after the first detection of the slight retinal change at the nasal border of the optic disk, in 2001, examination revealed complete spontaneous regression of the retinal vascular changes at the border of the papilla (Fig. 1 b).

2. A 36-year-old woman with VHL revealed a retinal edema with slight vascular changes at the superior border in her right eye in 1984 (Fig. 2 a). The patient had kidney cysts. Her son and daughter also had v. Hippel-Lindau disease.

In addition, a small angioma at the temporal border of the papilla in her right eye was present. The patient also showed a peripheral microangioma in her left eye treated by Argon laser coagulation in 1986. By 1992, the coagulated peripheral retinal tumors had been completely destroyed. Only scars in the peripheral retina of both eyes were found. Visual acuity remained 20/20. In 2001, a new peripheral small angioma in the inferior retina was detected, also successfully treated by laser. In 2004, two new microangiomas in the periphery of the right eye were found and coagulated by laser. The microangioma at the temporal border of the papilla was practically unchanged when compared to photos from 1984.

A control examination 20 years later, in 2004, revealed a complete regression of the retinal edema with slight scar formation at the superior border in the right eye. Two small hemangiomas have developed at the temporal border (Fig. 2 b).

3. A 12-year-old boy, the son of the second patient, was first examined in 1984. He had several hemangioblastomas (spinal cord, cerebrum, and epididymis, also cysts in the pancreas and kidneys) as well as an endolymphatic sac tumor.

The eye examination showed a retinal *microaneurysm* inferior to the optic disc in his right eye. He revealed

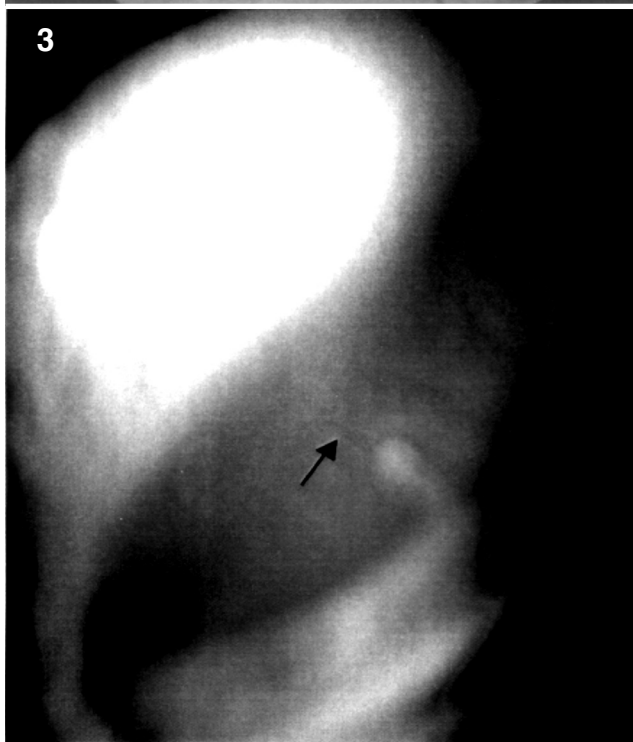
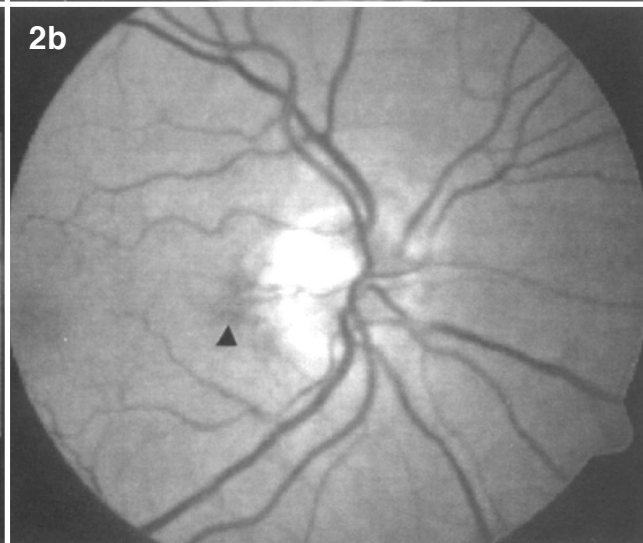
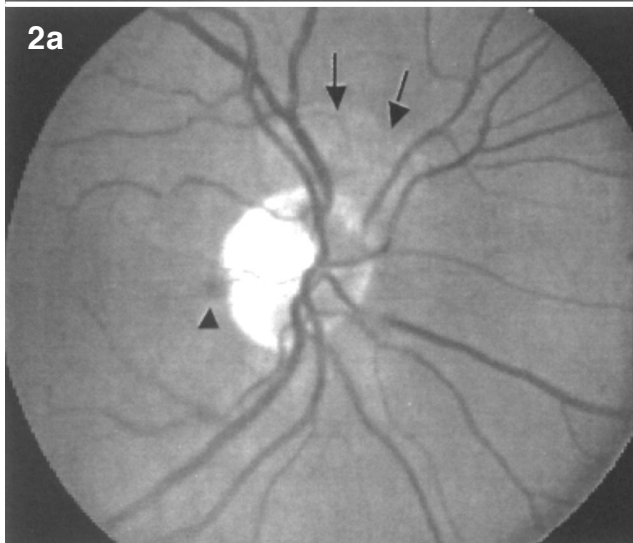
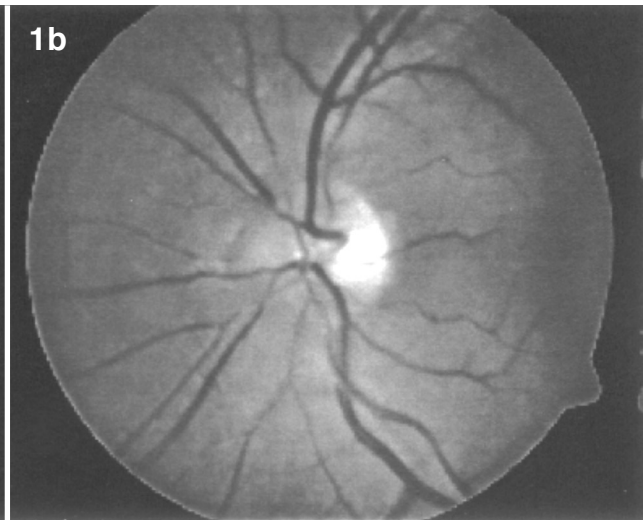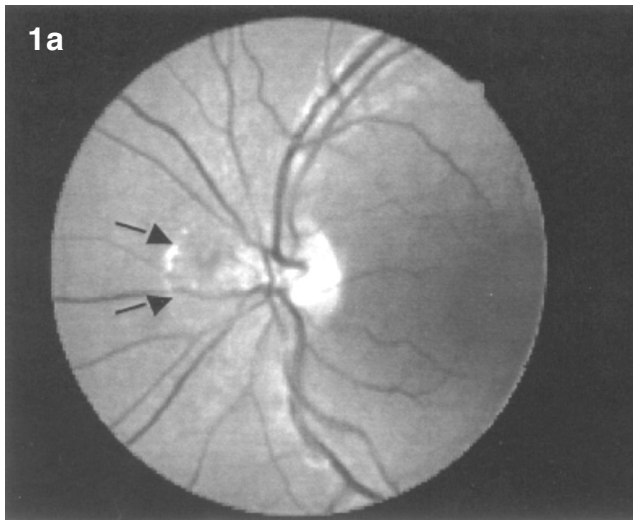


Fig. 1 a. LE. Retinal vascular anomaly with a circumscribed small edema at the nasal border of the optic disk (arrows)

Fig. 1 b. LE. Complete spontaneous regression of retinal lesion.

Fig. 2 a. RE. Circumscribed slight vascular changes in the retina at the superior border (arrow). Small angioma at the temporal border of the papilla (arrow head)

Fig. 2 b. RE. Regression of retinal lesion with slight scar formation. Two small angiomas at temporal border have developed (arrow).

Fig. 3. RE. Small fibrotic white hemangioma with a pigmented feeder vessel (arrow) (photo through a Goldmann contact glass).

several peripheral microangiomas in the retinal periphery of both eyes. The small retinal lesions were successfully treated by Argon laser in 1992 and 2004.

The follow-up examination in 2004 revealed that the microaneurysm observed in 1984 had completely disappeared.

4. A 41-year-old woman with suspected VHL was examined once in 2004. Her daughter had a pheochromocytoma. Our patient showed a small fibrotic white hemangioma with a pigmented feeder vessel in the superior periphery of her right eye. The pigmented feeder vessel could be a sign of spontaneous regression of the white tumor. Visual acuity was 20/20 in both eyes (Fig. 3).

DISCUSSION

Spontaneous regression of retinal lesions in our patients with VHL have been documented. The disappearance of the changes has been verified by longterm follow-up observation. There are some reports in the literature demonstrating regression. Whitson et al. (1986) histologically examined a pigmented retinal area and found capillary-like changes indicating spontaneous regression of an angiomatous lesion in a patient with VHL. Rumbaur (1941) described a shrunken, white-coloured tumor with wrinkled surface with no dilated feeding vessels in a 54-year-old man. Rumbaur presumed that those changes in the retinal tumor in VHL occurred spontaneously.

Webster et al. (1999) found peripheral angiomatous lesions that had not been previously treated in five eyes of five patients. The white lesions showed attenuated feeding vessels and remained hyperfluorescent on fluorescein angiography. However, it is not clear whether those changes occurred by tumor regression.

An additional explanation could be that retinal hemangiomas develop primarily with fibrosis, and that the feeder vessels were small from the start. We found a fibrotic hemangioma in a 21-year-old woman (Schmidt et al. 1987). The fact that a white retinal lesion with narrow feeder vessels can occur in such a young patient means that a congenital change can also occur.

The minor vascular changes in patients with VHL herein described are considered to be rare lesions. Every retinal anomaly in VHL should be controlled by follow-up examination and documentation. In case the retinal lesion increases in size, however, treatment is necessary.

REFERENCES

- Rumbaur W. (1941) Über Angiomatosis retinae (v. Hippel-Lindausche Krankheit). *Klin Monatsbl Augenheilkd* 106: 168-198
- Schmidt D, Neumann HPH. (1987) Atypische retinale Veränderungen bei v. Hippel-Lindau-Syndrom. *Fortschr Ophthalmol* 84: 187-189
- Webster AR, Maher ER, Moore AT. (1999) Clinical characteristics of ocular angiomatosis in von Hippel-Lindau disease and correlation with germline mutation. *Arch Ophthalmol* 117: 371-378
- Whitson JT, Welch RB, Green WR. (1986) Von Hippel-Lindau disease: Case report of a patient with spontaneous regression of a retinal angioma. *Retina* 6: 253-259

Received: August 23, 2005 / Accepted: October 14, 2005

Address for correspondence:

Prof. Dr. Dieter Schmidt
Univ.-Augenklinik
Killianstr. 5
D-79106 Freiburg, Germany
Fax: +49-(0)761/270-4075
E-Mail: Dieter.Schmidt@uniklinik-freiburg.de