

# MANAGEMENT OF Fournier's GANGRENE

## REPORT OF 7 CASES AND REVIEW OF THE LITERATURE

J. Fajdic<sup>1</sup>, D. Bukovic<sup>2</sup>, Z. Hrgovic<sup>3</sup>, M. Habek<sup>4</sup>, D. Gugic<sup>5</sup>, D. Jonas<sup>6</sup>, W. J. Fassbender<sup>7</sup>

<sup>1</sup>General Hospital Pozega, <sup>2</sup>Clinic for woman's diseases Zagreb, <sup>3</sup>Gynecologic Clinic - Clinical Hospital Center Osijek,

<sup>4</sup>University of Zagreb, Medical School, <sup>5</sup>Oncologic Clinic - Clinical Hospital Center Osijek, Croatia

<sup>6</sup>Department of Adult and Paediatric Urology, J.W. Goethe University, Frankfurt am Main,

<sup>7</sup>Dept. for Internal Medicine, Hospital zum HL. Geist Kempen, Akad. Lehrkrankenhaus der Universität Düsseldorf, Kempen, Germany

### Abstract

Fournier's gangrene is a rare infection characterized with fast-progressing myonecrosis, that affect regions of perineum, genitalia and perianal area. This retrospective study presents authors' experiences and their principles in early diagnosis and treatment of Fournier's gangrene. The goal of this paper is to point out numerous diagnostically and therapeutic difficulties that lead to a high mortality if not recognized in time. We here describe seven male patients with myonecrosis and necrotising fasciitis in scrotal, perianal and perineal regions. Average age was 61 years (from 57 to 66 years of age), and average length of treatment was 25.8 days (from 14 to 36 days), with lethality of 14% (one case). We have recognised diabetes mellitus as risk factor, together with urethrostenosis, and other diseases of the perianal region (hemorrhoids, anal fissure, abscesses). Our hypothesis is that the key of the successful treatment is to treat as soon as symptoms onset, early and aggressive necrectomy under broad antibiotic protection. We also emphasize the possibility of recurrence of this disease even several years after treatment.

*Key words:* gangrene, Fournier, mixed infection, necrectomy

### INTRODUCTION

Fournier's gangrene is a rare infection characterized with fast-progressing myonecrosis, that affect regions of perineum, genitalia and perianal area. It is more common in men, between 40 and 70 years of age, and less frequent in women, but has also been described in children younger than 15 years. Unfortunately it is characterized with high lethality, especially if diagnosed in late stages of disease.

There are two main pathways for disease spreading. First from the gastrointestinal tract, usually from anorectal region (abscesses) after surgical treatment of hemorrhoids, trauma of rectum, etc. The second is from the urogenital tract after prolonged use of urinary catheters, periurethritis, instrumental dilatation of stenosis of urethra. The factors that benefit onset in all variants of this disease are: diabetes mellitus, alco-

holism, drugs, immunological deficiencies, malignant diseases, renal and hepatic insufficiency. Pathogenesis of this disease is still not known exactly. Infection advances through genital fascia (Buck and Dartos), perineal fascia (Colles) as well as fascia of abdominal wall (Scarpa), in all directions, and can even reach up to armpit. Although it is evident that the synergism of microorganisms is present in the development of this infection, hemocultures are usually negative. [1] The following bacteria are common: E. Coli, Pseudomonas aeruginosa, Streptococcus putridis, Staphylococcus, Klebsiella, but also several anaerobic bacteria like Bacteroides, Clostridium perfringens and Bacillus fragilis.

The infection initiates under normal-looking skin. Although the symptoms usually are redness and edema of the skin of scrotum and perineum (and occasionally on penis), symptoms can also be discrete. It is more often in cases where deeply hidden abscesses (such as ischiorectal abscesses) are observed. Suspected diagnosis is based on clinical presentation in up to 80% of cases.

### PATIENTS AND METHODS

In a period from 1997 to 2000, we treated a total of seven patients. They were between 57 and 66 years of age (61 in average). All patients were males. Three had diabetes mellitus. In three patients necrosis started in scrotal area, and in four in perianal region. Beside diabetes, we also recorded other risk factors: urethrostenosis (2 patients), hemorrhoids (1 patient), anal fissure (1 patient), ischiorectal abscess (1 patient), while in one patient we did not reveal any risk factors.

### RESULTS

In the patients with perianal spread of disease, we recorded so called black annular necrosis (Black spot), from which the inflammation was spreading rapidly in deeper layers of tissue (Figs. 1-4). Among infectious agents,  $\beta$ -hemolytic streptococcus, Enterococcus faecalis, Pseudomonas aeruginosa and Proteus were isolated, but mixed bacterial flora was also a common finding. Among anaerobias, we also found Bacillus fragilis and Clostridium perfringens to be common.

Table 1. Patients with Fournier's gangrene.

Patient	N.P.	N.N.	K.B.	P.M.	S.P.	K.R.	A.M.
Age (years)	66	57	64	61	58	60	62
Sex	M	M	M	M	M	M	M
Duration of disease before treatment (days)	5	3	7	9	4	6	4
Other factors	Ureterostenosis Diabetes mellitus	Diabetes mellitus	Noduli haemorrhoidales	Abscessus ischiorectalis, Diabetes mellitus	Fissura ani	Ureterostenosis	-
Microbiology	_hemol. Streptococcus	Proteus	_hemol. Streptococcus	Chlostridium Enterococcus perfringens faecalis Pseudomonas	Enterococcus faecalis	_hemol. Streptococcus	Proteus Pseudomonas
Antibiotics	Ampicilin Gentamicin	Cefuroxim Gentamicin	Ampicilin Gentamicin Metronidazolom	Cefuroxim Gentamicin Metronidazolom	Cefuroxim Gentamicin Metronidazolom	Norfloxacin Cefuroxim	Ciprofloxacilin Metronidazolom
Procedure	Necrectomy	Incision and drainage, Necrectomy	Incision and drainage, Necrectomy	Incision and drainage, Necrectomy	Incision and drainage, Necrectomy	Necrectomy, Orchidectomy	Necrectomy

Table 2. Outcome of treatment

Patient	N.P.	N.N.	K.B.	P.M.	S.P.	K.R.	A.M.
Age (years)	66	57	64	61	58	60	62
Sex	Male	Male	Male	Male	Male	Male	Male
Duration of treatment (days)	18	28	14	36	25	28	32
Outcome	cured	cured	cuerd	deceased	cured	cured	cured
Colostoma	no	no	no	yes	no	no	no
Cystostoma	no	no	no	no	no	no	no
Definitive surgical treatment	Secondary sutures	Secondary sutures	Secondary sutures	-	Secondary sutures	Spontaneous resolution	Spontaneous resolution

Duration of symptoms before admission was ranging from 3 to 9 days (5.4 on average). Several patients had to be treated with extensive necrectomy in general anesthesia which was repeated daily, until satisfactory state without obvious infection was reached. In three patients, we used incision and drainage in early phase of treatment, and in later course of treatment we also used necrectomy. We usually used combined antibiotic therapy, using several antibiotics, due to mixed infection.

In four patients we reconstructed destroyed tissue on scrotum and perineum (using secondary sutures), without transplantation, while in two cases the whole area was re-epithelialized spontaneously. Covering the defects with large movable skin flap was not necessary. [2, 3] The treatment lasted 25.8 days on average, ranging from 14 up to 36 days. We had to perform orchidectomy in one patient, since the inflammation had reached the testicles. The patients with inflammation of perianal and perineal region, were broad incised, excision of necrotic tissue was preformed, we man-

aged to preserve the function of sphincter. One patient died, while six were discharged from hospital as cured. Hyperbaric oxygenation was not considered. In one patient we had to perform colostomy, and in one other suprapubic cystostomy was necessary.

## DISCUSSION

This rare disease is characterized with a high mortality, ranging from 7% up to 75% [4-7]. In our series, only one patient (14.3%) died from this condition. In other studies, diabetes mellitus is the most common condition associated with Fournier gangrene, up to 55.6% cases [8]. Although extremely rare, it has been described in females and children [9-10].

Despite the well-known and accepted theory of intravascular spreading of infection with obliterating endarteritis in hypoxic surrounding that helps development of anaerobic conditions with necrosis, Fournier gangrene is still an unclear entity. In all available stud-

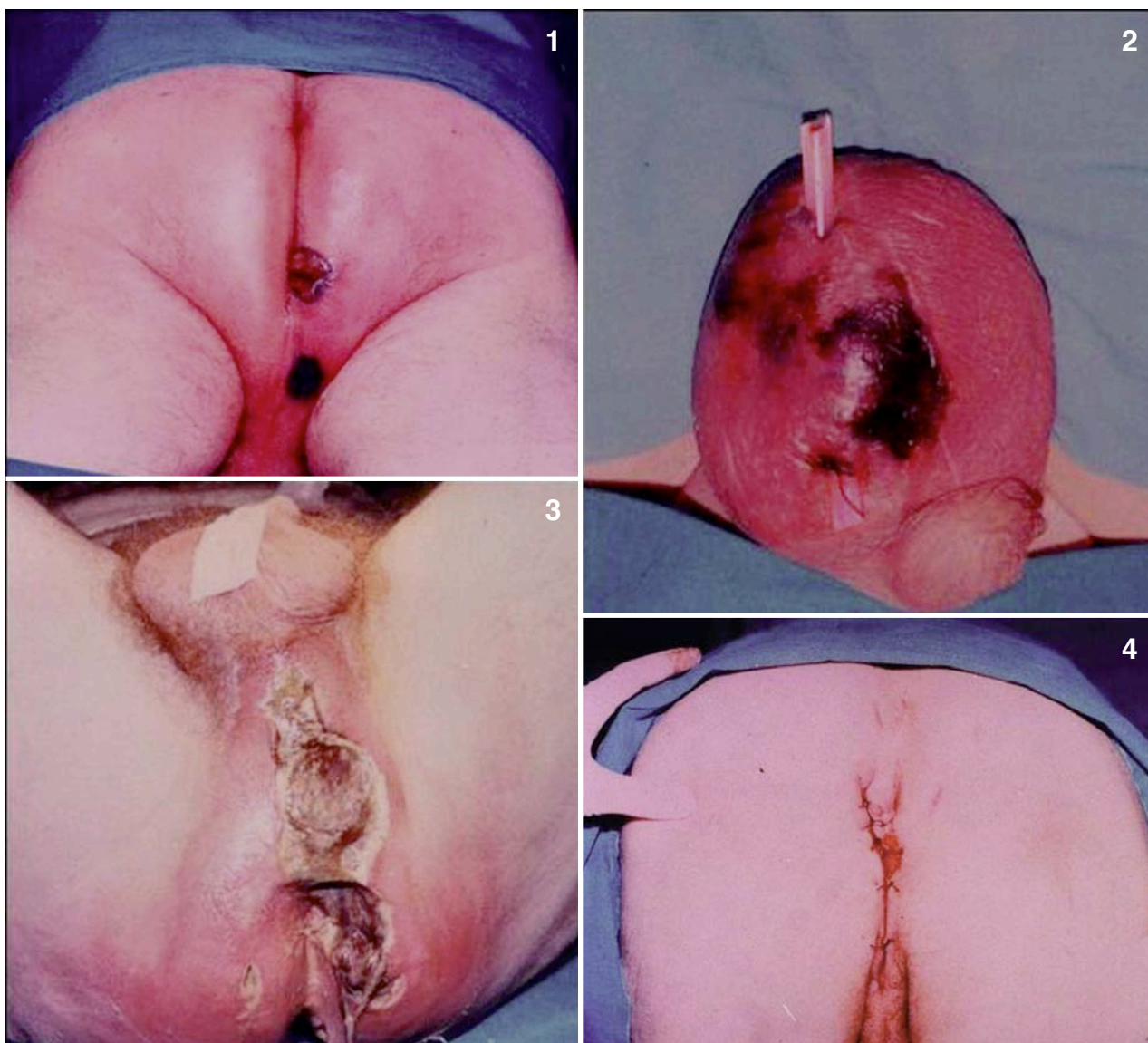


Fig. 1. Example of necrosis at the admission - "black spot"

Fig. 2. Example of initial necrotic process on scrotum (Patient K.R.)

Fig. 3. Necrotising myofasciitis on day six from onset of disease (Patient N.N.)

Fig. 4. Secondary sutures of perianal region – last phase of treatment (Patient N.N.)

ies there are descriptions of infections caused by many microorganisms with a substantial number of anaerobes, that makes escalating of antibiotic treatment necessary. Pande and Mewara [11] recorded marked decrease in frequency of perineal infections in the period of 1938-1975, that is caused by broader use of antibiotics, and better hospital care.

Rea and Wyrick [12] emphasize the significance of time period between onset of infection and beginning of the treatment, stating that most patients that survived, have been treated within 4 days from beginning of infection, while in deceased patients treatment started at 7th day of infection. Similar results have been reported by other authors [13]. Our patients were admitted at day 5 (average) since the beginning of the infection. All patients reported strong pain, this was also observed by other authors [13].

Diagnostic procedures that provided us with useful information were ultrasound and computed tomography, while necrosis and suppurative infection were diagnosed by aspirational biopsy. The positive outcome of therapy in six patients is an effect of aggressive surgical therapy, using incisions, drainage, and necrectomy accompanied by antibiotic treatment.

In time of Fournier, this disease was considered to be idiopathic. To date we know the causes, and usually it is quickly differentiated whether the origin of infection is the gastrointestinal or urogenital tract. An example of our last patient shows the possibility of development of this rare and severe disease from simple anal fissure. This points out, that early clinical examination of patients with pain and signs of infection in perineal region is of extreme importance, even if the presentation of inflammation is not alarming [13].

We would also like to mention that several papers describe application of drugs and other additive substances, as possible causes of infection that leads to Fournier gangrene [14], and also patients with alcohol-induced hepatitis are affected [15]. Different authors report additional risk factors that speed up the course of this disease and complicate therapy (such as diabetes mellitus, abuse of alcohol and drugs, oligophreny, patients with decubital wounds and immunologically compromised patients [8,13,16-19]).

Throughout the literature it can be noted, that all authors advise early and aggressive treatment [20]. Using such an approach in most of our patients, we had an average treatment duration of 25.8 days. Morgana et al. emphasized application of anti-gangrenous serum, that, among other effects, eliminates unpleasant odour of necrotic tissue, as we recorded in one patient that acquired Fournier's gangrene from sacral decubitus [16].

Problems such as derivation of urine by cystostoma, or feces by colostoma, are controversial and are addressed differently in several treatment protocols, and we found that it should be applied in accordance to individual patient condition [21-22].

Since our only deceased patient was admitted late in course of disease - 9 days from onset of infection - forming of ischiorectal abscess, we find that this delay in surgical treatment was the main cause of lethal outcome. This conclusion is based upon several similar cases reported in literature where fatal outcome of treatment of Fournier's gangrene in older patients rises up to 60% [4,13]. Possibility of recurrence of this condition even several years after treatment is described.

#### REFERENCES

1. Wolach MD, MacDermott JP, Stone AR, deVere White RW. Treatment and complications of Fournier's gangrene. *Br J Urol* 1989;64:310-4.
2. Kayikcioglu A. A new technique in scrotal reconstruction: short gracilis flap. *Urology* 2003;61:1254-6.
3. Monteiro E, Carvalho P, Costa P, Ferraro A. "Inner thigh lift flap" for Fournier gangrene of the scrotum. *Plast Reconstr Surg* 2002;110:1372-3.
4. Burge TS. Necrotizing fasciitis--the hazards of delay. *J R Soc Med* 1995;88:342P-343P.
5. Norton KS, Johnson LW, Perry T, Perry KH, Schon JK, Zibari GB. Management of Fournier's gangrene: an eleven year retrospective analysis of early recognition, diagnosis, and treatment. *Am Surg.* 2002;68:709-13.
6. Fillo J, Cervenakov I, Labas P, Mardiak J, Szoldova K, Kopečný M, Szeiff S, Mal'a M, Chovan D. Fournier's gangrene: can aggressive treatment save life? *Int Urol Nephrol* 2001;33:533-6.
7. Morpurgo E, Galandiuk S. Fournier's gangrene. *Surg Clin North Am* 2002;82:1213-24.
8. Korkut M, Icoz G, Dayangac M, Akgun E, Yeniay L, Erdogan O, Cal C. Outcome analysis in patients with Fournier's gangrene: report of 45 cases. *Dis Colon Rectum* 2003;46:649-52.
9. Yoshida C, Kojima K, Shinagawa K, Hashimoto D, Asakura S, Takata S, Tanimoto M. Fournier's gangrene after unrelated cord blood stem cell transplantation. *Ann Hematol* 2002;81:538-9.
10. Guneren E, Keskin M, Uysal OA, Ariturk E, Kalayci AG. Fournier's gangrene as a complication of varicella in a 15-month-old boy. *J Pediatr Surg* 2002;37:1632-3.
11. Pande SK, Mewara PC. Fournier's gangrene: a report of 5 cases. *Br J Surg* 1976 ;63:479-81.
12. Rea WJ, Wyrick WJ Jr. Necrotizing fasciitis. *Ann Surg* 1970;172:957-64.
13. Ben-Aharon U, Borenstein A, Eisenkraft S, Lifschitz O, Leviav A. Extensive necrotizing soft tissue infection of the perineum. *Isr J Med Sci* 1996;32:745-9.
14. Mouraviev VB, Pautler SE, Hayman WP. Fournier's gangrene following penile self-injection with cocaine. *Scand J Urol Nephrol* 2002;36:317-8.
15. Zenda T, Kobayashi T, Miyamoto S, Okada T. Severe alcoholic hepatitis accompanied by Fournier's gangrene. *Eur J Gastroenterol Hepatol* 2003;15:419-22.
16. Nisbet AA, Thompson IM. Impact of diabetes mellitus on the presentation and outcomes of Fournier's gangrene. *Urology* 2002;60:775-9.
17. Murphy BL, Pezzullo JA. Images in medicine. Fournier's gangrene. *Med Health R I* 2003;86:121.
18. Chawla SN, Gallop C, Mydlo JH. Fournier's gangrene: an analysis of repeated surgical debridement. *Eur Urol* 2003;43:572-5.
19. Gurdal M, Yucebas E, Tekin A, Beysel M, Aslan R, Sengor F. Predisposing factors and treatment outcome in Fournier's gangrene. Analysis of 28 cases. *Urol Int* 2003;70:286-90.
20. Singh G, Sinha SK, Adhikary S, Babu KS, Ray P, Khanna SK. Necrotising infections of soft tissues--a clinical profile. *Eur J Surg* 2002;168:366-71.
21. Kearney GP, Carling PC. Fournier's gangrene: an approach to its management. *J Urol* 1983;130:695-8.
22. Woodside JR. Necrotizing fasciitis after neonatal circumcision. *Am J Dis Child* 1980;134:301-2.

Received: July 17, 2006 / Accepted: February 23, 2007

#### Address for correspondence:

Priv. Doz. Dr. med. Walter Josef Faßbender  
Hospital zum Hl. Geist Kempen  
Akad. Lehrkrankenhaus der Universität Düsseldorf  
von Broichhausen-Allee 1  
47906 Kempen/Ndrh.  
Germany  
Tel.: +49-2152-142 381  
Fax: +49-2152-142 311